



# Prolonged Premature Preterm Rupture of Membranes: A Successful Case from The Dominican Republic

**Authors:** Megan Dorame,<sup>1</sup> \*Rahina Sheikh<sup>2</sup>

1. Departments of Anthropology and Public Health, University of Minnesota Twin-Cities, USA
  2. Department of Public Health, University of Nevada Las Vegas, Nevada, USA
- \*Correspondence to [Rahina.sheikh123@gmail.com](mailto:Rahina.sheikh123@gmail.com)

**Disclosure:** The authors have declared no conflicts of interest.

**Acknowledgements:** The authors would like to acknowledge the Global Health Leaders program, especially the research advisor, for providing guidance, tools, and resources to write the case study. Thank you to the hospital and medical team for releasing information about this significant case. The medical staff obtained informed, written consent from the patient for the publication of this case report and any accompanying images.

**Received:** 18.08.24

**Accepted:** 15.11.24

**Keywords:** Maternal morbidity, neonatal morbidity, neonatal mortality, preterm birth, preterm premature rupture of membranes (PPROM).

**Citation:** EMJ. 2025; <https://doi.org/10.33590/emj/KDDX2140>

## Abstract

Preterm premature rupture of the membranes (PPROM) impacts 5–7% of all pregnancies. A pregnancy is considered previable, the fetus having a low chance of surviving before 22 weeks of gestation. Preterm birth is the leading cause of neonatal mortality. PPRM is associated with health complications for the neonates and mothers. Some of the neonatal morbidities include respiratory distress syndrome, infection, pulmonary hypoplasia, and sepsis. Some of the maternal complications are chorioamnionitis, endometritis, and placental abruption. This case study describes a clinical case from the Dominican Republic where there was a PPRM that occurred at 16 weeks of gestation. Furthermore, the latency period from the initial rupture to preterm birth was approximately 18 weeks, which is longer than the average latency period. Despite these complications, the patient successfully gave birth at 33.6 weeks to a relatively healthy baby.

## Key Points

1. Prolonged preterm premature rupture of membranes (PPROM) affects 5–7% of pregnancies and is a major contributor to both neonatal and maternal health complications.

2. A case-control study was conducted to examine a clinical case from the Dominican Republic where PPRM occurred at 16 weeks gestation, with a prolonged latency of 18 weeks.

3. Despite complications, effective PPROM management enabled the patient to deliver a healthy baby. Further research is needed to understand PPROM prevalence in the Dominican Republic and evaluate current treatment and management strategies.

## INTRODUCTION

This case study describes a clinical case from the Dominican Republic where there was a preterm premature rupture of membranes (PPROM) that occurred at 16 weeks of gestation. It is important to note that there is a lack of specific PPROM statistics and information from the Dominican Republic.<sup>1</sup> A pregnancy is determined to be pre-viable when the fetus is at a stage of maturity where it has a low chance of surviving outside of the uterus. Generally, anything before 22 weeks of gestation is thought to be nonviable.<sup>2</sup> PPROM occurs in approximately 5–7% of all births,<sup>3</sup> but PPROM occurring “near the limit of fetal viability”<sup>4</sup> only complicates around 0.04% of pregnancies and has a higher morbidity.<sup>4</sup> The cause for the premature rupture is unknown, but there are several risk factors, such as history of prematurity, maternal age (adolescence or being over the age of 35 years), decreased BMI, multiple pregnancies, and genital infections.<sup>5</sup> There are many complications associated with PPROM for both the neonate and the mother. In neonates, some of the common morbidities include respiratory distress syndrome (RDS), infection, pulmonary hypoplasia, arterial hypotension, bronchopulmonary dysplasia (BPD), and sepsis.<sup>4</sup> Some of the maternal complications are chorioamnionitis, endometritis, and placental abruption.<sup>4</sup> There are two management options for mothers with PPROM, expectant management and the termination of pregnancy (TOP). Mothers who chose the expectant management option have a 60.2% chance of developing maternal morbidity, which is 3.47 times more likely than those who chose TOP.<sup>6</sup> Globally, complications from preterm birth before 37 weeks are the leading cause of neonatal mortality.<sup>7</sup> The literature on PPROM shows varying survival rates for infants from approximately 20% to 56%. However, in instances where PPROM

occurred before 20 weeks of gestation, the survival rate is around 18%.<sup>8</sup> Moreover, only approximately 15.7% of cases where the neonate survives to discharge the mother does not experience any kind of morbidity.<sup>6</sup>

Although there has been a steady decline in preterm births, preterm neonates have a higher mortality rate in developing nations.<sup>9</sup> Sociodemographic factors that increase the risk of PPROM include low socioeconomic status, lack of education, and race/ethnicity.<sup>5</sup> Lower socioeconomic status and poverty severely restrict access to health services, including prenatal and newborn care, nutritious foods, and other vital amenities. Moreover, those with lower incomes are more likely to have difficult working conditions, such as strenuous and labour-intensive jobs with long working hours, which is associated with PPROM.<sup>5</sup>

This clinical case is significant because both the mother and infant were determined to be relatively healthy after birth despite PPROM occurring at 16 weeks before the fetus was deemed to be viable and the presence of anhydramnios. Furthermore, the latency period between the initial PPROM and birth was approximately 18 weeks, which is much longer than the average latency period. There is a lack of information and statistics on PPROM from the Dominican Republic, which makes this clinical case that much more important.

## CASE

The patient is a 32-year-old woman from the Dominican Republic. This is the patient’s first pregnancy and has no reported history of toxic habits, surgical, or medical history. However, it is noted that the patient has A RH-positive blood. The patient had their first menstruation at 12 years old and had a regular cycle that typically lasted 4 days following the first occurrence.

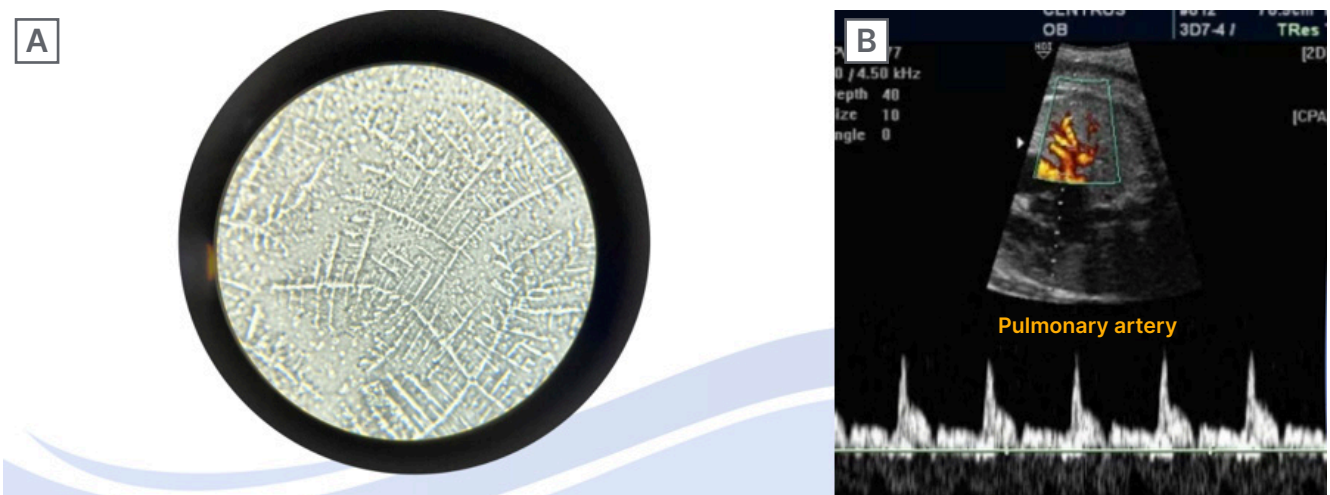
The patient went to the emergency room after experiencing transvaginal fluid leakage for 3 hours. During the initial physical examination, 12 weeks sonography was extrapolated with a caudal cephalic length of 5.4 cm, dating a gestational age of 16 weeks. The results of the initial physical examination showed that the patient's head, neck, chest, heart, genitalia, and extremities had no pathologies. An examination of the lungs revealed the presence of a vesicular murmur and no pathologic rales. The examination of the patient's abdomen documented that it was globose at the expense of adipose tissue and pregnant uterus, had adequate peristalsis, indeterminate at Leopold's maneuvers, uterine height 17 cm, no uterine dilation, fetal heart rate 149, depressible, manageable, and not painful on palpation. The speculotomy showed that the patient had a cervix of normal appearance and configuration, and outflow of fluid in slight amounts with the performance of the Valsalva maneuver, obtaining sample for arborization test (Figure 1A). The vaginal examination determined the patient had a normothermic vagina; posterior cervix, 2 cm long, permeable to the external cervical os; the bony pelvis had a sacral promontory that was not palpable, divergent spines, and a broad subpubic arch. The patient had weekly

follow-up appointments to check on the patient's and the fetus' progress following the positive diagnosis with PPRM.

During the diagnostic assessment, an arborization test, sonography, and physical examination were performed to determine the prognosis. Expectant management was considered on an outpatient basis, and frequent laboratory tests were required. These laboratory tests were performed during the assessment period and continued to be performed during the monitoring period until birth: blood count, glycaemia, urine test, C-reactive protein, culture of vaginal secretion, and urine culture (Table 1 and 2).

Upon admission at 16 weeks, the patient was given 875 mg of amoxicillin and 125 mg of clavulanic acid to take every 8 hours for a period of 48 hours. From 16–24 weeks, the patient was given 300 mg of ferrous sulfate, 5 mg of folic acid, and 600 mg of calcium to take every 24 hours. At the 24-week consultation, the patient was admitted to the hospital and the medical team administered intravenous ampicillin and erythromycin every 6 hours for 48 hours. This was followed by oral amoxicillin and erythromycin every 8 hours for 5 days. Additionally, the medical team administered

**Figure 1: Arborization test results and a fetal Doppler test.**



**A)** Arborization test results. The crystallisation present in the arborization test indicates a positive test result. This confirms the occurrence of a rupture of membranes. **B)** Fetal Doppler Test. Index of Pulsatility for the Pulmonary Artery in 3.15 seconds.

Table 1: First, second, and third trimester results.

	First Trimester		
Blood count	Day 79 of pregnancy	Day 99 of pregnancy	11.3 g/dL
Haemoglobin	11.2 g/dL	11.0 g/dL	36.2%
Haematocrit	29.5%	31.6%	146 $\mu$ L
Platelets	157 $\mu$ L	128 $\mu$ L	13.0 X 10 <sup>3</sup>
Leukocytes	6.9 $\times$ 10 <sup>3</sup>	13.4 X 10 <sup>3</sup>	84 mg/dL
Glycaemia	89 mg/dL	85 mg/dL	(+) 12–15 leu
Urine	(-) 5–6 leu	(-) 8–9 leu	Negative
PCR	Negative	Negative	11.3 g/dL

	Second Trimester					
Blood count	Day 145 of pregnancy	Day 151 of pregnancy	Day 159 of pregnancy	Day 162 of pregnancy	Day 165 of pregnancy	Day 169 of pregnancy
Haemoglobin	11.2 g/dL	11.0 g/dL	10.8 g/dL	11.2 g/dL	12.5 g/dL	12.3 g/dL
Haematocrit	29.5%	31.6%	30.1%	36.3%	40.5%	30.5%
Platelets	157 mil	128 mil	139 mil	147 mil	159 mil	152 mil
Leukocytes	10.3 $\times$ 10 <sup>3</sup>	13.4 $\times$ 10 <sup>3</sup>	13.5 $\times$ 10 <sup>3</sup>	13.5 $\times$ 10 <sup>3</sup>	12.2 $\times$ 10 <sup>3</sup>	13.0 $\times$ 10 <sup>3</sup>
Glycaemia	69 mg/dL	90 mg/dL	83 mg/dL	85 mg/dL	90 mg/dL	94 mg/dL
Urine	(-) 4–6 leu	(+) 8–9 leu	(-) 6–8 leu	(-) 5–8 leu	(-) 7–8 leu	(-) 3–4 leu
PCR	-	-	-	-	-	-

	Third Trimester					
Blood count	Day 172 of pregnancy	Day 175 of pregnancy	Day 179 of pregnancy	Day 184 of pregnancy	Day 189 of pregnancy	Day 194 of pregnancy
Haemoglobin	11.0 g/dL	10.8 g/dL	10.7 g/dL	10.2 g/dL	11.5 g/dL	12.0 g/dL
Haematocrit	30.6%	30.4%	30.2%	31.3%	33.2%	37.1%
Platelets	142 mil	156 mil	149 mil	150 mil	159 mil	160 mil
Leukocytes	13.6 $\times$ 10 <sup>3</sup>	11.6 $\times$ 10 <sup>3</sup>	11.5 $\times$ 10 <sup>3</sup>	12.5 $\times$ 10 <sup>3</sup>	12.0 $\times$ 10 <sup>3</sup>	11.5 $\times$ 10 <sup>3</sup>
Glycaemia	89 mg/dL	97 mg/dL	83 mg/dL	85 mg/dL	90 mg/dL	96 mg/dL
Urine	(-) 3–6 leu	(-) 8–10 leu	(-) 6–7 leu	(-) 5–6 leu	(-) 3–4 leu	(-) 3–5 leu
PCR	-	-	-	-	-	-

leu: leukocyte esterase; mil: million; PCR: polymerase chain reaction.

**Table 2: Infection test results.**

	First trimester	Second trimester	Third trimester
<b>Falcaemia</b>	Negative	Not tested	Not tested
<b>Toxoplasmosis</b>	Negative	Not tested	Not tested
<b>Viral panel</b>	HIV negative, VDRL negative, HBSAG negative, HVC negative	HIV negative, VDRL negative, HBSAG negative, HVC negative	HIV negative, VDRL negative, HBSAG negative, HVC negative
<b>Vaginal discharge cultures</b>	Negative	Fosfomycin-sensitive klebsiella SPP	Negative
<b>Urine culture</b>	Negative	Negative	Negative

HBSAG: hepatitis B surface antigen; HVC: hepatitis C virus; VDRL: venereal disease research laboratory.

6 mg of dexamethasone intramuscularly every 12 hours for 48 hours to induce fetal lung maturity. Following this admission, weekly follow-ups were scheduled where blood count was measured, and urine reactive test and obstetrical sonography were conducted. At 30 weeks, a vaginal discharge culture tested positive for Klebsiella, the patient was treated with fosfomycin for 7 days and repeated the control. A biophysical profile was measured every week from 28 weeks onwards, and a fetal doppler with pulmonary artery pulsatility index was done at 33 weeks (Figure 1B).

At 33.6 weeks, the patient was admitted to the hospital centre and presented a pattern of three moderate contractions in 10 minutes. A vaginal examination revealed a normothermic vagina; a posterior cervix, 1.5 cm long; the bony pelvis spines were not prominent, had a wide subpubic arch, and was non-palpable. A diagnosis of threatened preterm labour and incorrect pelvic presentation was given. The patient gave birth at 33.6 weeks via a caesarean section and was found to have anhydramnios. The preterm newborn was developmentally appropriate for a gestational age of 34 weeks. The newborn was a male, with a head circumference of 34 cm, thoracic perimeter of 32 cm, was 45 cm long, had an Apgar score of 8/9, and weighed 2,760 g at birth. The newborn

spent 2 weeks inpatient in the perinatology admission area and was discharged in stable condition. A follow-up for both the mother and baby was conducted 2 months later by the obstetrics department.

## DISCUSSION

Premature rupture of membranes in pregnancy complicates 0.04% of pregnancies.<sup>4</sup> It may be spontaneous or follow an invasive procedure such as amniocentesis or fetal surgery. Significant maternal complications related to premature rupture of membrane in previable pregnancy include chorioamnionitis, genital infections, sepsis, placental abruption, and retained placenta. With complications, such as bleeding, cramping, or fever, abortion is considered inevitable, and the uterus is evacuated. However, in cases without these complications, expectant management is an option. Neonatal morbidity is related to prematurity. In the clinical case, this patient experienced premature rupture of the membranes at 16 weeks, with a latency period of 18 weeks and anhydramnios.

In the Dominican Republic, medical facilities generally follow WHO guidelines for the treatment and management of PPROM. Larger hospitals in metropolitan areas are fully equipped, so they are

more likely to follow general guidelines. However, practices may differ from those in rural communities with fewer resources. Notably, there is a lack of research on the management of previable premature rupture in these settings. In this case, the hospital staff were thorough in providing care and routinely conducting follow-up care. The medical staff followed general clinical guidelines for PPROM.<sup>10</sup> Due to prolonged rupture coupled with a pelvic presentation that threatened preterm labour, the patient gave birth before reaching full term. At 24 weeks, the medical team initiated the Mercer Protocol, which involves administering intravenous ampicillin and erythromycin followed by oral amoxicillin and erythromycin. The staff also administered dexamethasone, an antenatal corticosteroid therapy for fetal lung maturation that is widely prescribed and recommended by WHO PPROM guidelines.<sup>11</sup> Corticosteroids have been shown to reduce the probability of severe neonatal outcomes and not increase the risk of infection for the mother or fetus.<sup>11</sup> Generally, the administration of antenatal corticosteroids is recommended and should be offered to PPROM patients who have no signs of infection from 24 weeks gestation onwards.<sup>10,11</sup> It should also be noted that the WHO PPROM guidelines caution against the use of antenatal corticosteroids in prolonged PPROM cases and when characteristics of sepsis are present.<sup>11</sup> At 16 weeks, the patient was given amoxicillin plus clavulanic acid 875 and 125 mg every 8 hours for 48 hours. The administration of both amoxicillin and clavulanic acid is not widely agreed upon. In some PPROM cases, if uterine dilation

has not started, administering both drugs is considered beneficial because the combination is able to treat a wider range of microorganisms.<sup>12</sup> However, in other cases, it is not recommended because of an increased risk of developing necrotising enterocolitis (NEC), a severe intestinal disease in neonates, and instead the use of erythromycin is advised.<sup>11,13</sup> An additional recommendation to reduce neonatal morbidity is to consider other options for fetal lung maturation therapies instead of prescribing dexamethasone. This is recommended because of the 18-week latency period between the rupture of membranes and birth in this case.

Given the lack of current statistics on the prevalence and management of PPROM in the Dominican Republic, the level of significance of this case is yet unknown. When looking at the current statistics available worldwide, this case does show clinical significance due to its success. In order to gain a better understanding of the level of its significance in the Dominican Republic, it is necessary to conduct further research. This case study is noteworthy not only for its success but also for its unique nature, with the potential to enhance neonatal and maternal health outcomes.

## ETHICAL CONSIDERATIONS

There were no ethical issues when conducting the case study. Informed, written consent was given by the medical staff and there was no personal, identifiable information linking the case to the patient.

### References

1. Pan American Health Organization. Perinatal information system. Available at: <https://www.sipplus.org/>. Last accessed: 23 June 2024.
2. Gkiougki E et al. Periviable birth: a review of ethical considerations. *Hippokratia*. 2021;25(1):1-7.
3. Herzlich J et al. Neonatal outcomes in women with preterm premature rupture of membranes at periviable gestational age. *Sci Rep*. 2022;12(1):11999.
4. Kraft K et al. Pre-viable preterm premature rupture of membranes under 20 weeks of pregnancy: a retrospective cohort analysis for potential outcome predictors. *Eur J Obstet Gynecol Reprod Biol*. 2022;278:177-82.
5. Bouvier D et al. Risk factors and outcomes of preterm premature rupture of membranes in a cohort of 6968 pregnant women prospectively recruited. *J Clin Med*. 2019;8(11):1987.
6. Sklar A et al. Maternal morbidity after preterm premature rupture of membranes at <24 weeks' gestation. *Am J Obstet Gynecol*. 2022;226(4):558.e1-11.
7. World Health Organization (WHO). Preterm birth. 2023. Available at: [https://www.who.int/news-room/fact-sheets/detail/preterm-birth#:~:text=Key%20facts,deaths%20in%202019%20\(2\)](https://www.who.int/news-room/fact-sheets/detail/preterm-birth#:~:text=Key%20facts,deaths%20in%202019%20(2)). Last accessed: 16 June 2024.
8. Gauthier-Moulinier H et al. Outcomes of pregnancies with preterm premature rupture of membranes

- occurring before 24 weeks of gestation: an 11-year observational study. *Int J Gynaecol Obstet.* 2023;162(2):590-5.
9. Díaz-Rodríguez A et al. Risk factors associated with preterm birth in the Dominican Republic: a case-control study. *BMJ.* 2021;11(12):e045399.
  10. Thompson AJ.; Royal College of Obstetricians and Gynaecologists. Care of women presenting with suspected preterm prelabour rupture of membranes from 24+0 weeks of gestation. *BJOG.* 2019;126(9):e152-66.
  11. World Health Organization (WHO). WHO recommendations on interventions to improve preterm birth outcomes. 2015. Available at: [https://iris.who.int/bitstream/handle/10665/183037/9789241508988\\_eng.pdf?sequence=1](https://iris.who.int/bitstream/handle/10665/183037/9789241508988_eng.pdf?sequence=1). Last accessed: 14 July 2024.
  12. Fetal Medicine Barcelona. Rotura Prematura De Membranas A Término Y Pretérmino. Available at: <https://fetalmedicinebarcelona.org/wp-content/uploads/2024/02/rotura-prematura-de-membranas-hcp-hsjd.pdf> Last accessed: 14 July 2024.
  13. Bohlița RE et al. Expectant management of PPROM improves neonatal outcome—a retrospective study of 562 patients. *J Clin Med.* 2021;11(1):214.